Uroradiology Tutorial For Medical Students

Lesson 2:

Ultrasound – Part 2

American Urological Association

Review

- In Ultrasound-1 you learned how ultrasounds are performed and some basic concepts
  - Sonodensity (ehogenicity) is not the same as tissue density as seen on x-rays or CT scans
    - Fat and air appear hyperechoic (very light)
  - Ultrasound orientation conventions
    - Longitudinal – cephalad on left side-caudad on the right
    - Transverse – right side is on the left as on KUB

Basic Renal Ultrasound Interpretation

- 4 true-false questions
  - Size normal?
    - Formula: Normal = 4 + age in years x .6 cm
  - Shape normal?
  - Parenchyma normal?
    - Regularly irregular
    - Remember, the pyramids are hypoechoic (darker)
    - Parenchyma is less echogenic (darker) than liver or spleen
  - Hydronephrosis?
    - 4 grades of hydronephrosis
- Ready for more cases?

Case History

- A 12-year-old boy with intermittent abdominal pain is referred to you after his pediatrician orders an ultrasound. The boy has had no hematuria, fevers, or any other urological symptoms.
- Exam: afebrile, BP=98/68 and completely normal
- While you wait for the study to load, calculate the normal kidney size for 12-year-olds.
- Length = 12 x 0.6 + 4 cm or 11.2 cm

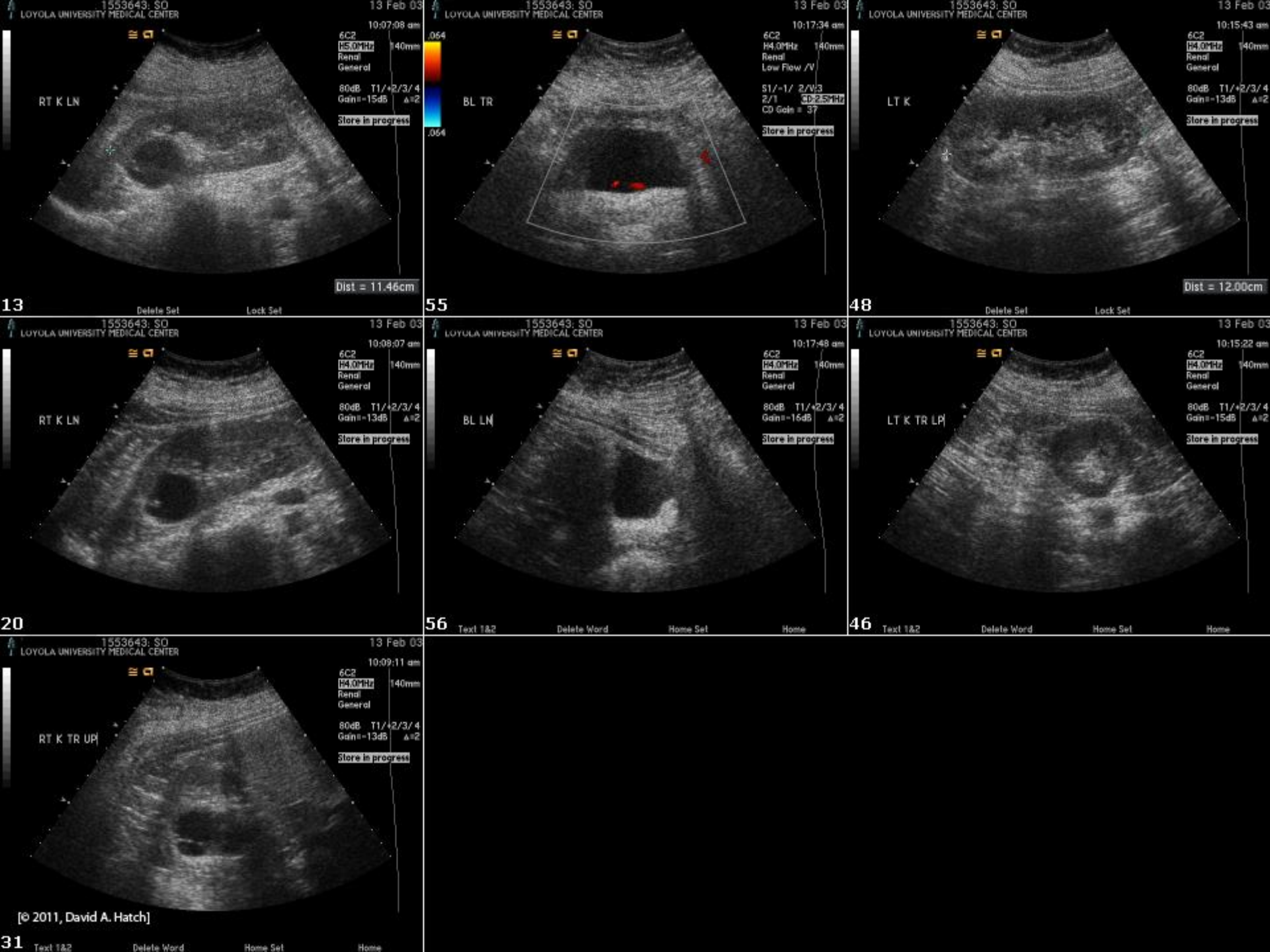
1553643: SO
LOYOLA UNIVERSITY MEDICAL CENTER
13 Feb 03
10:07:08 am
6C2
H5.0MHz 140mm
Renal
General
80dB T1/+2/3/4
Gain=-15dB Δ=2
Store in progress
RT K LN
Dist = 11.46cm
13
Delete Set
Lock Set
1553643: SO
LOYOLA UNIVERSITY MEDICAL CENTER
13 Feb 03
10:17:34 am
.064
.064
6C2
H4.0MHz 140mm
Renal
Low Flow /V
S1/-1/ 2/W3
2/1 CD 2.5MHz
CD Gain = 37
Store in progress
BL TR
55
1553643: SO
LOYOLA UNIVERSITY MEDICAL CENTER
13 Feb 03
10:15:43 am
6C2
H4.0MHz 140mm
Renal
General
80dB T1/+2/3/4
Gain=-13dB Δ=2
Store in progress
LT K
Dist = 12.00cm
48
Delete Set
Lock Set
1553643: SO
LOYOLA UNIVERSITY MEDICAL CENTER
13 Feb 03
10:08:07 am
6C2
H4.0MHz 140mm
Renal
General
80dB T1/+2/3/4
Gain=-13dB Δ=2
Store in progress
RT K LN
20
1553643: SO
LOYOLA UNIVERSITY MEDICAL CENTER
13 Feb 03
10:17:48 am
6C2
H4.0MHz 140mm
Renal
General
80dB T1/+2/3/4
Gain=-15dB Δ=2
Store in progress
BL LN
56
Text 1&2
Delete Word
Home Set
Home
1553643: SO
LOYOLA UNIVERSITY MEDICAL CENTER
13 Feb 03
10:15:22 am
6C2
H4.0MHz 140mm
Renal
General
80dB T1/+2/3/4
Gain=-15dB Δ=2
Store in progress
LT K TR LP
46
Text 1&2
Delete Word
Home Set
Home
1553643: SO
LOYOLA UNIVERSITY MEDICAL CENTER
13 Feb 03
10:09:11 am
6C2
H4.0MHz 140mm
Renal
General
80dB T1/+2/3/4
Gain=-13dB Δ=2
Store in progress
RT K TR UP
[© 2011, David A. Hatch]
31
Text 1&2
Delete Word
Home Set
Home

Your interpretation?

- Size:
- Shape:
- Parenchyma:
- Hydronephrosis?

How Did You Do?

- Size: Right-11.4 cm (normal). Left 12.0 (normal?)
  - Yes. The left kidney is typically longer than the right
- Shape: Right-normal. Left-normal.
- Parenchyma: Both kidneys show a heterogeneous pattern with pyramids and a central sinus echo stripe.
- Hydronephrosis?

Look at the right kidney. What is that?

- Location?
- Shape?
- Echo pattern
  (cystic v. solid)?

Look at the right kidney. What is that?

- Location: Upper pole, clearly within the parenchyma
- Shape: round on both transverse and longitudinal scans, so we know that it is sperical
- Echo pattern (cystic v. solid): cystic, but it has a thin web of tissue extending though the cystic structure

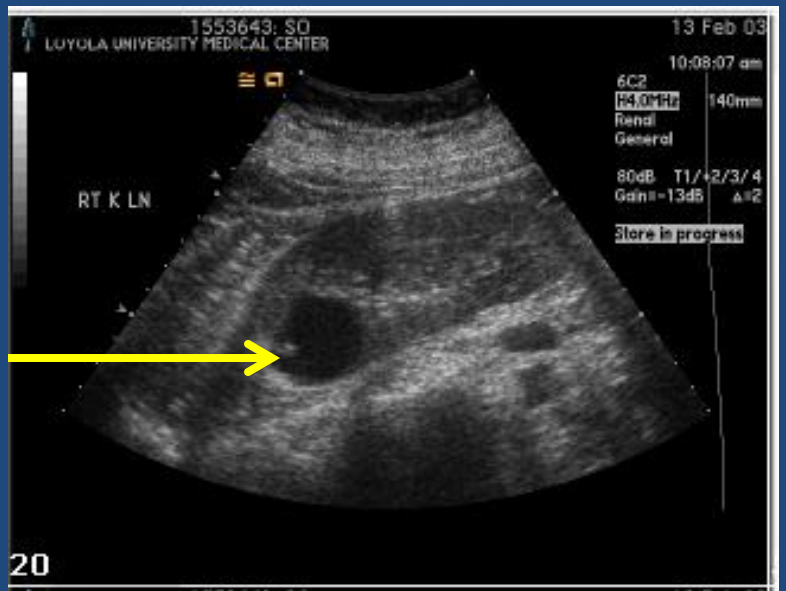

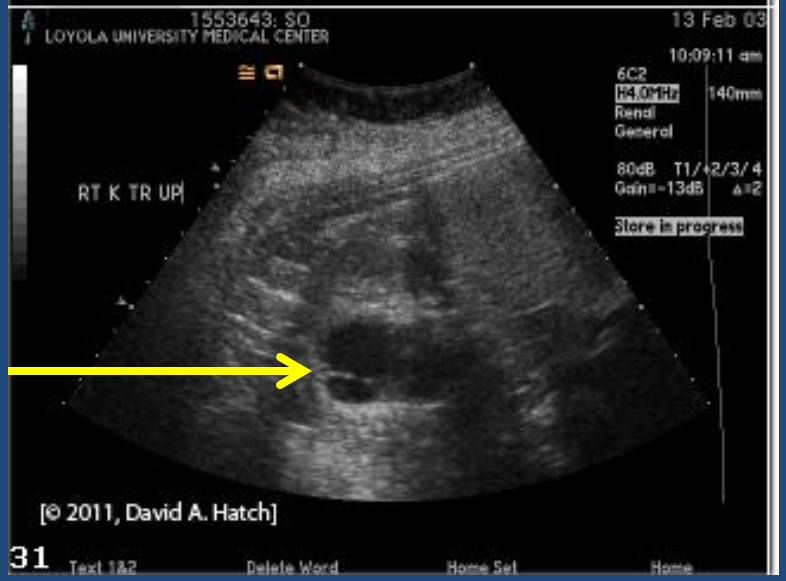

Analysis of Findings

- This structure is hypoechoic like hydronephrosis, but it's only seen in the upper pole.
- The web or septum isn't typical of hydroneprhsis.
- It's a renal cyst. Most renal cysts are found extending to the surface of the kidney, but they can be surrounded by parenchyma.

Case History

- A 6-year-old girl is referred for consultation after suffering several urinary tract infections. She has no other significant medical history.
- Exam: Healthy female. BP=92/64. Abdomen and genitalia are completely normal.
- Her pediatrician ordered a renal and bladder ultrasound. Take a look.

LOYOLA UNIVERSITY MEDICAL CENTER
17 Apr 03
9:40:48 am
LONG RT
8V5 6.5MHz 80mm Pelvic General Pwr= 0dB MI=1.1
85dB S1/+1/2/4 Gain= -8dB Δ=2
Store in progress
Dist = 7.47cm

LOYOLA UNIVERSITY MEDICAL CENTER
17 Apr 03
9:46:16 am
RT LN
8V5 5.5MHz 80mm Pelvic General Pwr= 0dB MI=1.3
85dB S1/+1/2/4 Gain= -8dB Δ=2
Store in progress

LOYOLA UNIVERSITY MEDICAL CENTER
17 Apr 03
9:43:32 am
LT K LN
8V5 6.5MHz 80mm Pelvic General Pwr= 0dB MI=1.1
85dB S1/+1/2/4 Gain= -8dB Δ=2
Store in progress
Dist = 6.04cm

18 Delete Set Lock Set

LOYOLA UNIVERSITY MEDICAL CENTER
17 Apr 03
9:39:55 am
LONG RT
8V5 7.5MHz 80mm Pelvic General Pwr= 0dB MI=0.9
85dB S1/+1/2/4 Gain= -6dB Δ=2
Store in progress

45 Text 1&2 Delete Word Home Set Home

LOYOLA UNIVERSITY MEDICAL CENTER
17 Apr 03
9:37:17 am
LN BL RT
8V5 7.5MHz 90mm Pelvic General Pwr= 0dB MI=0.9
85dB S1/+1/2/4 Gain= -4dB Δ=2
Store in progress

34 Delete Set Lock Set

LOYOLA UNIVERSITY MEDICAL CENTER
17 Apr 03
9:44:50 am
LT K TR MP
8V5 6.5MHz 80mm Pelvic General Pwr= 0dB MI=1.1
85dB S1/+1/2/4 Gain= -8dB Δ=2
Store in progress

14

4 Text 1&2 Delete Word Home Set Home

LOYOLA UNIVERSITY MEDICAL CENTER
17 Apr 03
9:41:47 am
TRANS RT
MP
8V5 6.5MHz 80mm Pelvic General Pwr= 0dB MI=1.1
85dB S1/+1/2/4 Gain= -8dB Δ=2
Store in progress

41

LOYOLA UNIVERSITY MEDICAL CENTER
17 Apr 03
9:37:52 am
TR BL
8V5 7.5MHz 60mm Pelvic General Pwr= 0dB MI=0.9
85dB S1/+1/2/4 Gain= -6dB Δ=2
Store in progress

[© 2011, David A. Hatch]

24

6 Text 1&2 Delete Word Home Set Home

Your interpretation, Doctor?

- Size:
- Shape:
- Parenchyma:
- Hydronephrosis?

How Did You Do?

- Size: Both normal (6 x 0.6 + 4 cm = 7.6 cm)
- Shape: Both normal
- Parenchyma: Both normal
- Hydronephrosis? Let’s look a little closer.

Describe what you see.

- 2 cystic (hypoechoic) areas in the right kidney. The lower pole (right side of the image) cystic area is less regular than the upper pole area.
- Hypoechoic object near the bladder

  extends into the bladder
- What is it?

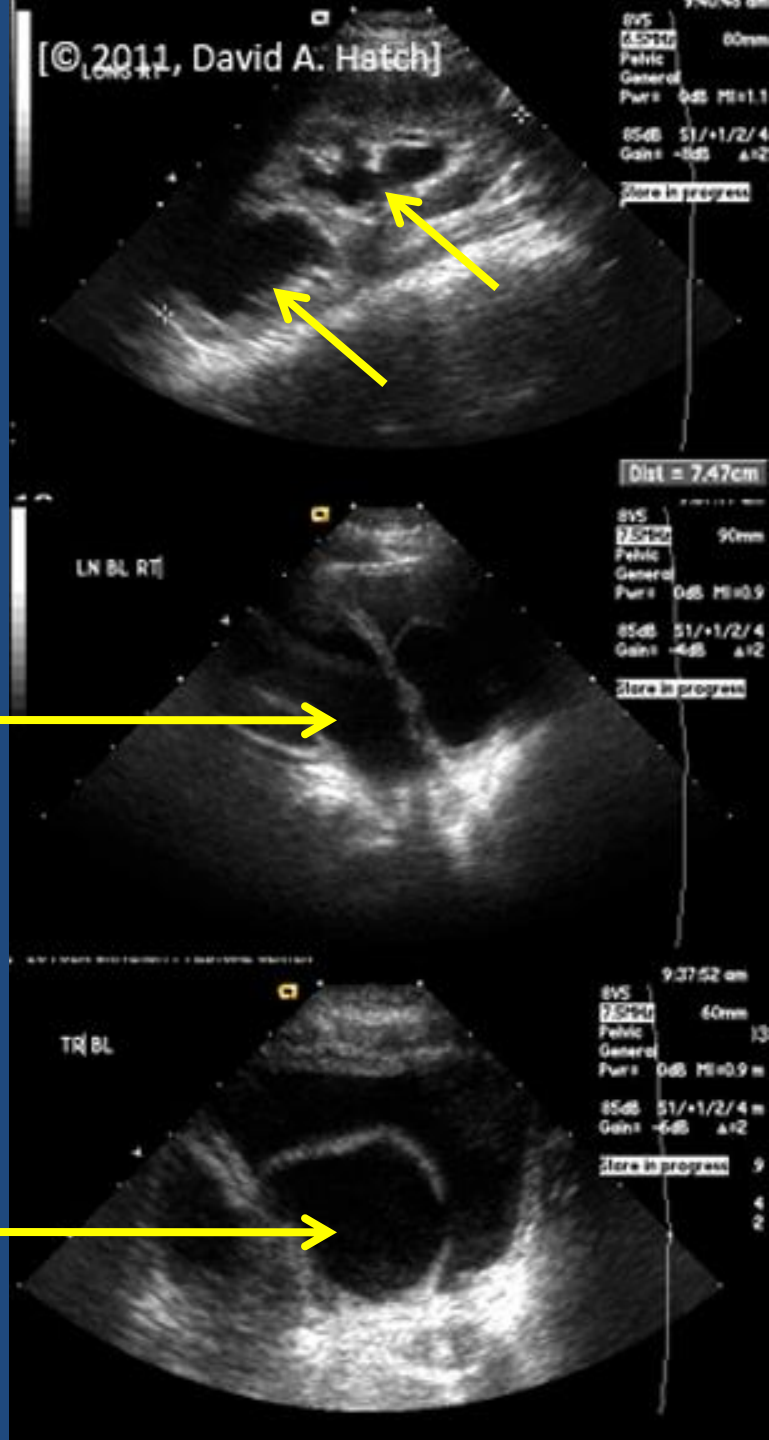

Ureterocele

- Ureter + cele [*sac*]
- A cystic dilation of the distal ureter within the bladder
- Ureteroceles can occur with single ureters or with ureteric duplication (two separate collecting systems). Which pattern does this child have?

Case Analysis-Ureterocele

- This child has a ureterocele associated with two completely separate ureters. The ureter is typically seen on ultrasound only when it is enlarged.
- When a ureterocele occurs with duplication, the ureterocele is always connected to the upper pole ureter. On ultrasound, we see only the dilated upper pole ureter in this case. A normal size ureter does not show up on ultrasound.

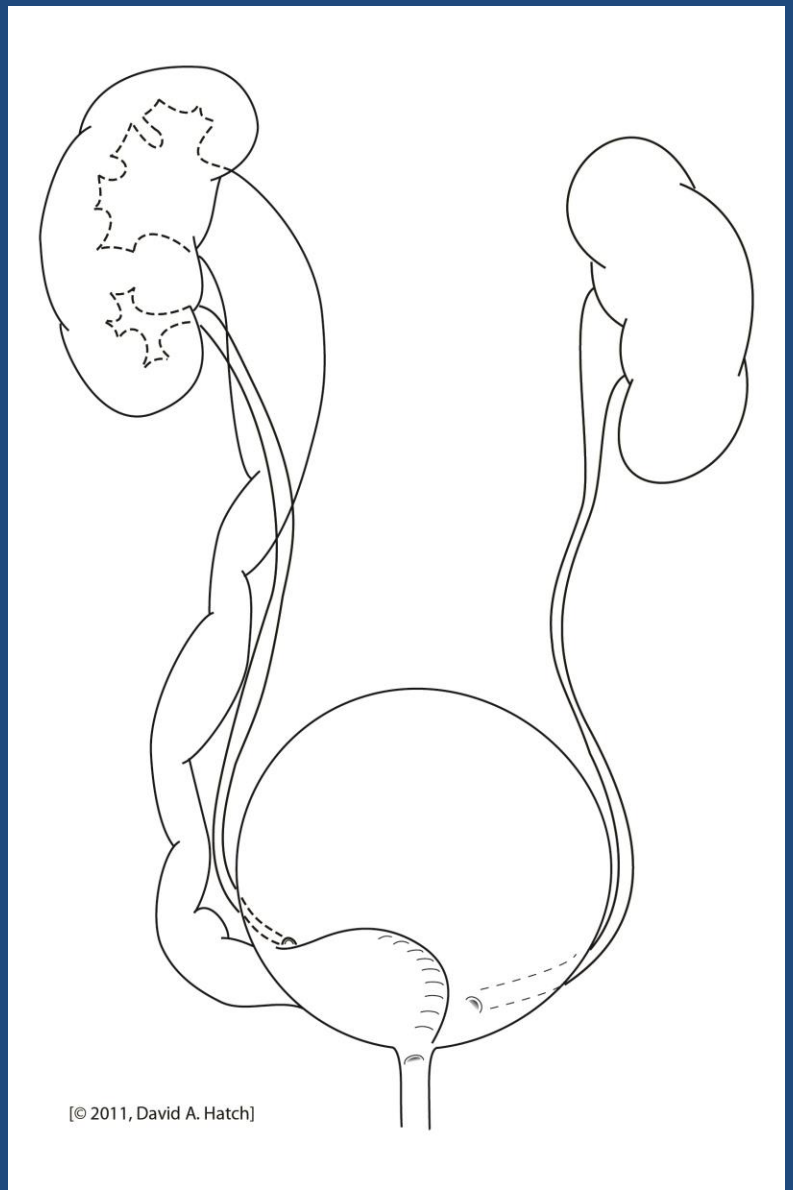

Case History

- You are called to see a newborn male. Prenatal ultrasounds have shown an abnormality. Unfortunately, the report and the images are temporarily unavailable. The obstetricians are all attending a meeting in Cancun.

- The baby is born at 36 weeks with APGARs of 8 / 9 / 9. The exam is completely normal.

- The pediatrician caring for the baby has already ordered an ultrasound.

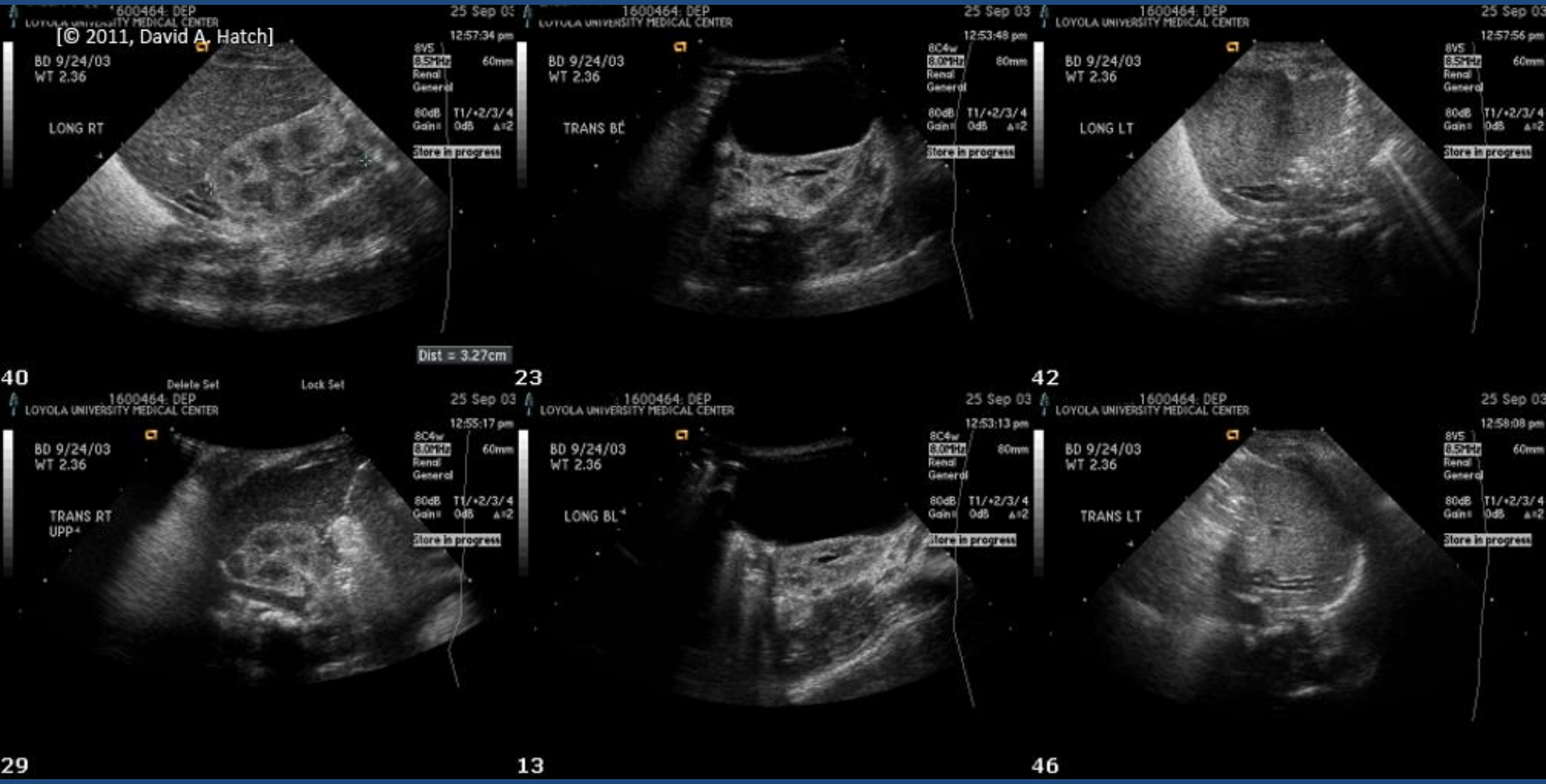
[© 2011, David A. Hatch]
1600464: DEP
LOYOLA UNIVERSITY MEDICAL CENTER
25 Sep 03
12:57:34 pm
BD 9/24/03
WT 2.36
LONG RT
Dist = 3.27cm
40
12:53:48 pm
TRANS BL
23
12:57:56 pm
LONG LT
42
Delete Sel
Lock Sel
12:55:17 pm
TRANS RT
UPP
29
12:53:13 pm
LONG BL
13
12:58:08 pm
TRANS LT
46

What is your reading of the ultrasound?

- Size:
- Shape:
- Parenchyma:
- Hydronephrosis:

Interpretation

- Size:
  - Right - 3.27 (expected: 36 mm + age = 3.6 cm)
  - Left - ?
- Shape:
  - Right - normal
  - Left - ?
- Parenchyma:
  - Right – normal
  - Left - ?
- Hydronephrosis:
  - Right – normal
  - Left - ?

What's up with the left kidney?

- Is it absent?
  - Remember that if one kidney is absent, the other will grow larger to compensate.
  - The right kidney is only 3.27 cm. If it were a solitary kidney, we would expect that it would be significantly larger than 3.6 cm.
- Is it somewhere other than in the renal fossa?
  - Where else could the kidney be?

Look again

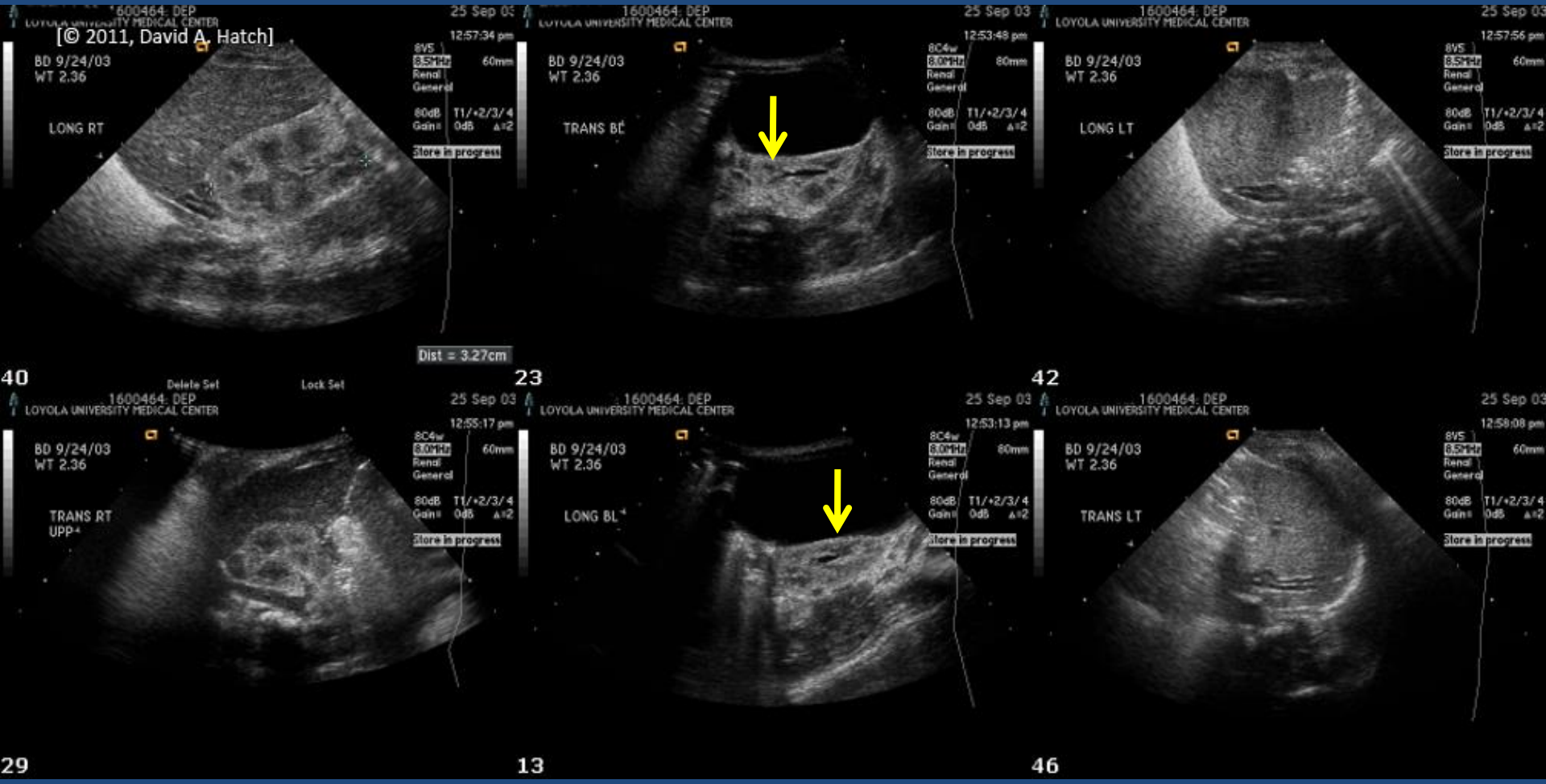

- What's behind the bladder?

Look closer

- Pyramids
- Renal pelvis

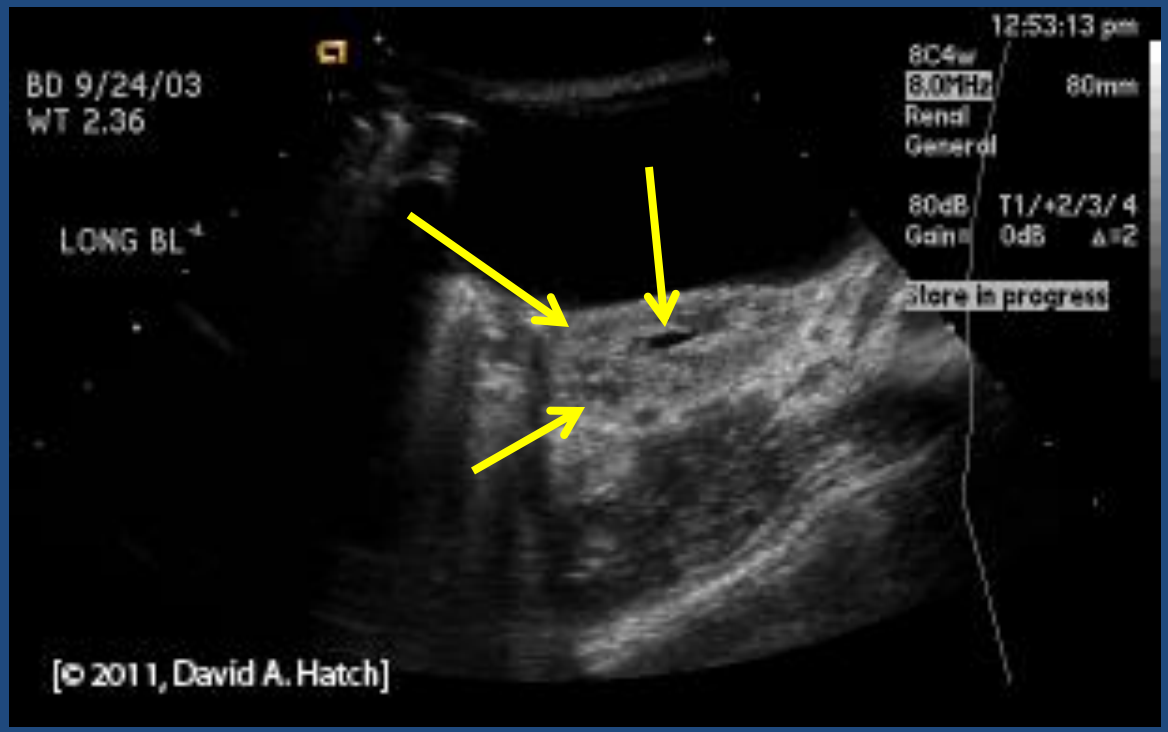

- Wait a minute. Why is the renal pelvis enlarged (we usually don’t see the pelvis unless hydronephrosis is present), or could that just be a prominent renal vein?

- Is there some way to tell the difference between hydronephrosis and vascular structures on ultrasound?

Doppler Effect

- Christian Doppler was an Austrian physicist who noticed that the frequency of waves emitted by a moving object vary depending on the speed and direction of that object relative to an observer.
- For example, say you're standing outside your hospital and an ambulance drives by, siren blaring. As the ambulance passes you and moves away, the pitch of the siren drops.

- Color Doppler ultrasound employs that principle to help us characterize objects. We know the frequency of the sound waves emitted by the transducer (say 9 mHz). If the echoes returning to the transducer are 8 mHz (lower pitch) then we know those echoes are coming from an object moving away from the transducer (typically an artery or vein).

- To be technically accurate we should point out that Doppler ultrasound detects velocity (distance moved / time) and direction (toward or away), not flow. In order to measure flow, one would have to know the volume moved (eg. mL / minute). Doppler only detects motion.
- Let’s look at a Doppler image of that kidney.

Color Doppler Ultrasound

There is motion in the image but not in the center of the kidney. The hypoechoic area is mild hydronephrosis.

Why is that kidney behind the bladder?

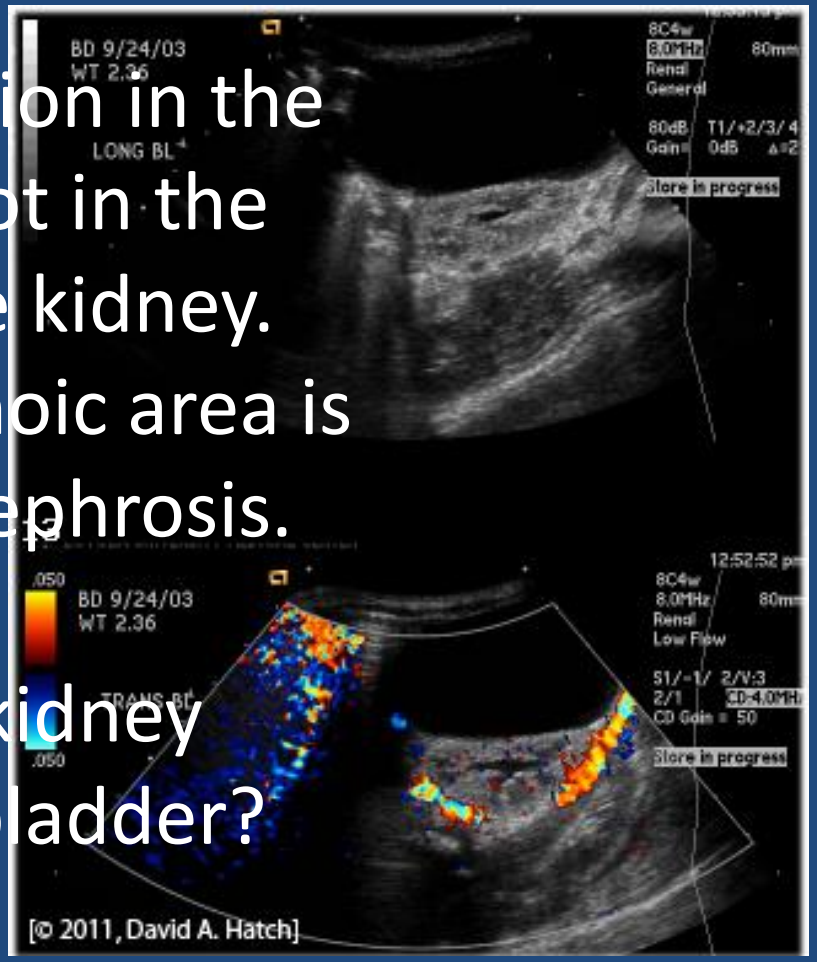

Ectopic Kidney

- During early fetal life, the kidney starts development near the bladder. As the fetus elongates, the kidney 'ascends' into the renal fossa, high in the retroperitoneum.

- If the kidney's ascent is impaired, it may reside in the pelvis, or anywhere along the path the normal ureter takes.

Ectopic Kidney

- Ectopic kidneys can be found anywhere from the pelvis to the thorax.

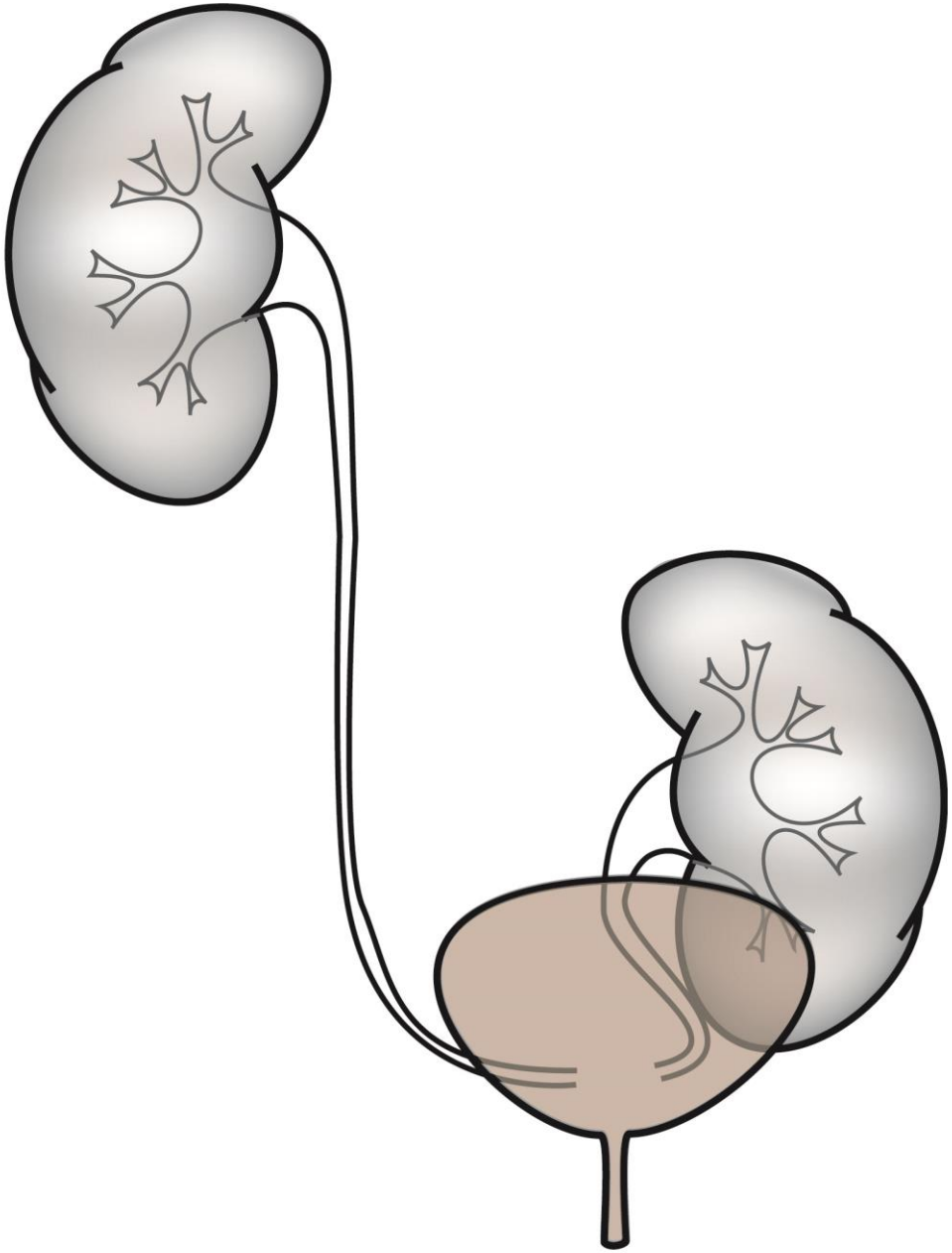

[© 2011, David A. Hatch]

Case History

- During a well child exam of a 7-year-old female, a mass was found in the left upper quadrant.
- Physical Exam

  Healthy appearing white female. P = 120, BP 98/62

  Abdomen is soft and non-tender. A non-tender mass is palpable on the left side. Genitalia are normal.

Imaging? What kind of imaging would be best?

Ultrasound

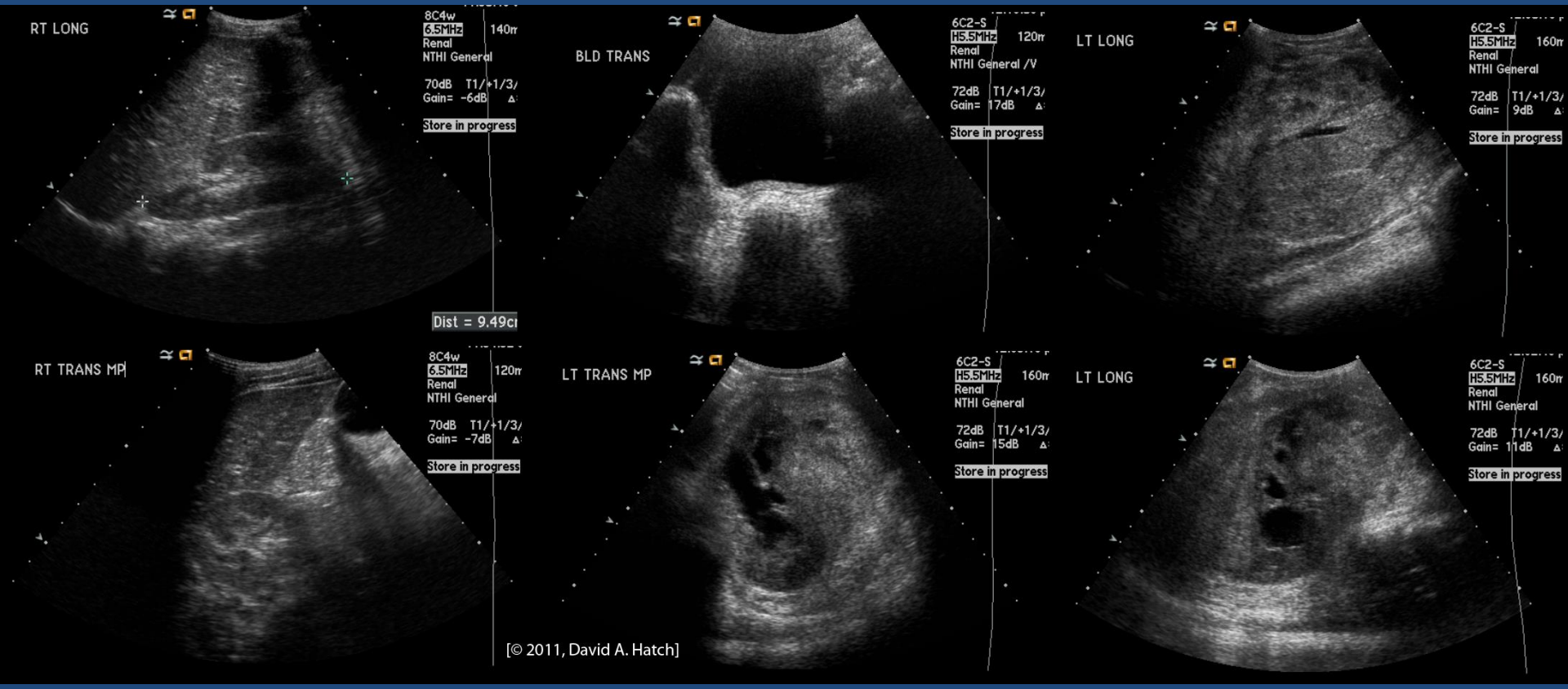

[© 2011, David A. Hatch]

Your ultrasound interpretation, Doctor?

- Right kidney
  - Size:
  - Shape:
  - Parenchyma:
  - Hydronephrosis:
- Left kidney
  - Size:
  - Shape:
  - Parenchyma:
  - Hydronephrosis:

How Did You Do?

- Right kidney
  - Size: 9.49 cm [Nl=7 x 0.6 + 4 cm = 8.2 cm] kidney large
  - Shape: normal
  - Parenchyma: normal
  - Hydronephrosis: none
- Left kidney
  - Size: no cross hairs, but take my word, it's large.
  - Shape: difficult to determine edges, but it looks irregular
  - Parenchyma: upper pole looks almost normal, but the lower pole is homogeneous. There are no pyramids, and the kidney is hyperechoic
  - Hydronephrosis: upper pole (Is something obstructing?)

Solid mass in left lower pole = Tumor

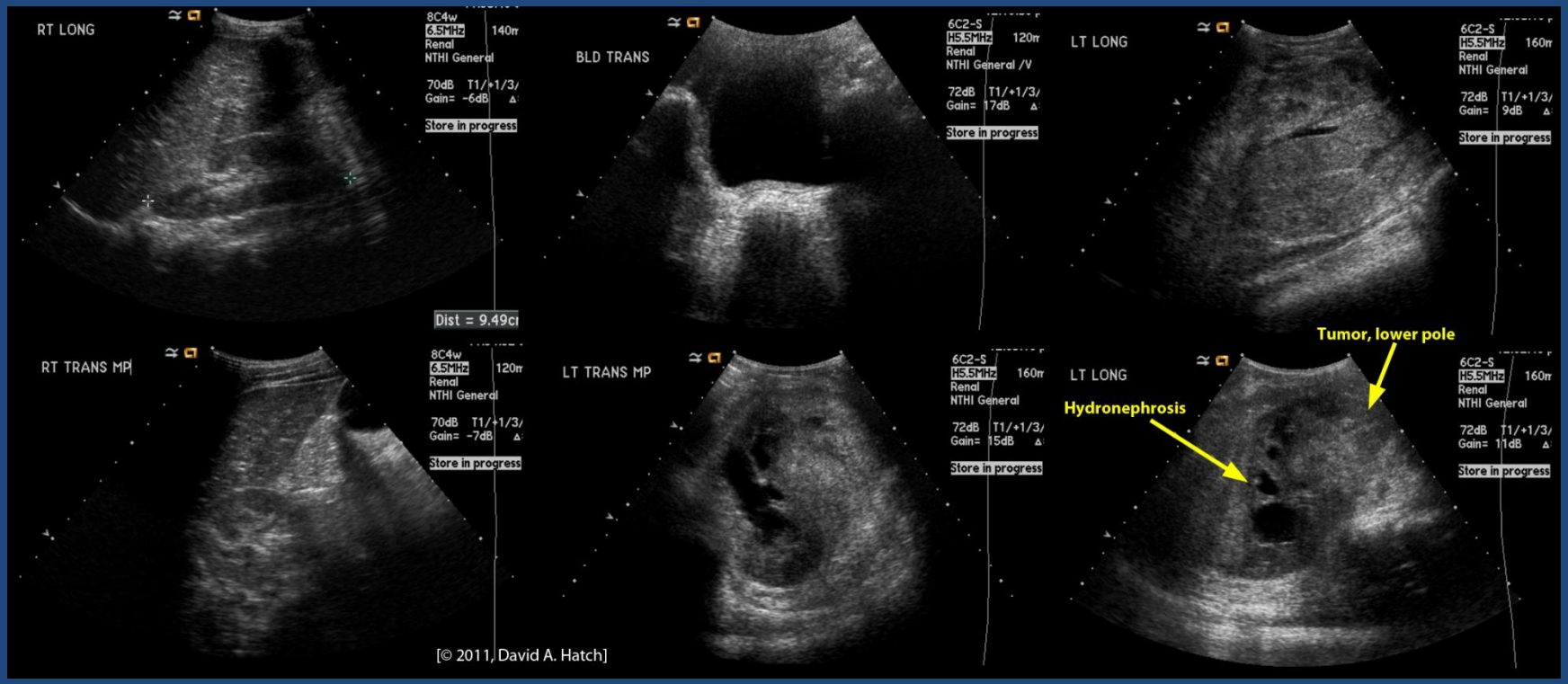

Diagnosis

- Wilms' tumor is the most common renal tumor of childhood.
  - Most occur in only one kidney.
  - They can expand rapidly, so prompt treatment is important.
  - Even if the tumor has spread beyond the capsule of the kidney, treatment with chemotherapy and occasionally with radiation is successful in the vast majority of affected children.

Ultrasound – Review

- Excellent study for determining solid v. cystic
- Conventions: Longitudinal – cephalad (left side of image), Caudal – right; Transverse-like a CT scan (as though the patient were facing you
- Kidney size (normal child) = Age (years) x 0.6 + 4 cm (full term)

Ultrasound – Review

- The most common cause of abdominal mass in a child is an anomaly of the kidney.
- The most common kidney anomaly presenting as a mass is hydronephrosis.
- The most common solid mass in the urinary tract in a child is a Wilms' tumor.
- Compensatory hypertrophy: if one of paired organs is missing, the contralateral organ will hypertrophy. If an apparently single kidney is normal size, look for an ectopic organ.

Ultrasound Review

- Ureterocele: dilation of the distal ureter within the bladder
  - Can occur with single or duplex collecting systems
  - In duplication, ureterocele drains the upper pole
- Unknown object?
  - Take a deep breath and then systematically describe it
  - Location, size, shape, echo pattern
- Doppler ultrasound can help to differentiate between vascular structures and hydronephrosis.

Congratulations!

- You’ve completed the ultrasound tutorial.
- You are ready to take the other genitourinary imaging tutorials.